

CLASS III MALOCCLUSION –Ways to combat it non surgically

Dr.Kishore msv, Dr.R.Lakshmi sravya, Dr.Varalakshmi chandaveni , Dr.Yaser Khan

SVS Institute of dental sciences

Abstract :- *Class III malocclusion is a condition where 1st molar of mandibular arch is placed ahead of maxillary 1st molar. Successful treatment of class III malocclusion depends on proper diagnosis and treatment planning. Diagnosing a class III case requires special attention on functional, soft tissue and systemic factors, along with identification of skeletal and dento-alveolar problems. For an individual with major skeletal disproportion it is necessary to consider surgical & orthodontic treatment to solve the problem. If the underlying discrepancy is mild or if the patient is not willing for surgical procedure consideration for camouflage may be given. This article gives an overview of various non-surgical methods proposed for dealing a class III malocclusion in adults.*

Key words: *Class III malocclusion, Skeletal, Dento-alveolar, Camouflage, Non-surgical*

1. Introduction

A class III malocclusion is a difficult anomaly to treat. Prevalence of Angle's class III malocclusion varies among different racial groups¹⁻⁴ with a range of 0 to 26.7% in different populations according to systematic review done by Hardy et al.⁵ Components of this skeletal problem frequently presents with a combination of variables like retrusive maxilla, protrusive maxillary incisors, retrusive mandibular incisors, a protrusive mandible, and a long lower facial height.⁶ Not all cases of class III malocclusion require surgery.⁷ Proper case selection is important in treating a patient with non-surgical therapy. This article describes the criteria for diagnosing and treating a class III malocclusion non-surgically.

2. Diagnosis and Clinical Examination

Diagnosing a case of Class III should involve few important clinical considerations.

2.1 Functional forward mandibular displacement/ functional class III:

Functional mandibular shifts may be secondary to respiratory needs, tongue size or pharyngeal dimensions may affect jaw size. Pseudo class III malocclusion is widely studied in children. Moyers defined it as positional mal-relationship with an acquired neuromuscular reflex pattern of mandibular closure.⁸ In Pseudo class III malocclusion,⁹⁻¹³ forward displacement of the mandible occurs during closure from the point of initial incisor contact to position in which the posterior teeth occlude.¹⁴ Diagnostic characteristics of pseudo-Class III malocclusion in children were described by Rabie et al(2000).¹⁵ If untreated early, this may affect the normal growth and development of the skeletal bases, leading to restricted maxillary growth and may be mandibular overgrowth developing into skeletal class III in adults.

Functional examination is of special importance while diagnosing a case of class III. Many a time's patients with class III present with combination of temporomandibular problems, asymmetry¹⁶ along with anterior cross bite. Measuring condylar displacement and centric relation before the start of comprehensive orthodontic treatment to unmask real jaw relationships will avoid possible misdiagnoses.¹⁷ Deviation posteri-

only while recording centric relation shows a favourable prognosis.

2.2 Skeletal jaw analysis:

Skeletal Class III sagittally can be a result of maxillary retrognathism, mandibular prognathism or a combination of both which must be identified taking support of cephalometry. Guyer et al¹⁸(1986) studied class III deformity in children between 13-15 years age and identified maxillary skeletal retrusion in 63% and mandibular protrusion in 66% of his sample. According to a recent study by Spalj et al,¹⁹ differential skeletal type among class III subjects was identified as given below.

Mandibular prognathism with a normal maxilla	43%
Maxillary retrognathism with a normal Mandibular position	19.6%
Maxillary retrognathism and mandibular prognathism	<5%

In vertical plane high mandibular plane angle and increased lower anterior facial height are often associated anatomical features in class III malocclusion.⁶ Elevated position of hyoid was another feature noted in class III subjects.²⁰

2.3 Dentoalveolar Examination:

Inclination of maxillary and mandibular incisors must be analysed using a standardized overlay tracing of the obtained cephalogram. Proclination of maxillary incisors and retroclination of mandibular incisors favours a surgical plan as the malocclusion is in a compensated state. Retroclined maxillary incisors and proclined mandibular incisors increase scope for orthodontic camouflage therapy.

2.4 Soft tissue examination:

Tongue analysis should be undertaken to diagnose any macroglossia, forward and depressed posture of tongue,²¹ articulation

defects, tongue thrusting habit, which can adversely affect stability post treatment. In a study conducted by Meenakshi et al,²² Lingual frenulum attachment was noticed high among class III subjects.

2.5 Acromegaly:

Mandibular prognathism and jaw thickening in adults may be due to deposition of periosteal bone in response to the excess growth hormone.²³ Hormonal assay of the individual should be advised to rule out excess growth hormone, when other features of this condition exist.

2.6 Growth changes:

Possibility for any late mandibular growth in the individual must be analysed which can hamper the entire treatment result.^{24,25}

3. Decision for treatment

3.1. Camouflage VS surgery: In case of severe skeletal discrepancy it is wise to consider surgical treatment. However, camouflage treatment with orthodontics alone reported success with remarkable soft tissue changes and profile improvement.²⁶ Tseng et al 2011⁷ conducted a receiver operating characteristic analysis to discriminate factors for diagnosing a surgical and non-surgical cases of class III. Six cephalometric measurements were identified as minimum number of discriminators required to obtain the optimum discriminant effectiveness of diagnosis between surgical and nonsurgical treatment of skeletal Class III malocclusions.

They are

Overjet	≤ -4.73 mm
Wits appraisal	≤ -11.18 mm
L1-MP angle	≤ 80.8
Mx/Mn ratio	$\leq 65.9\%$;
Overbite	≤ -0.18
Gonial angle	≥ 120.8

Four out of these six measurements suggest a surgical treatment.

4. Non surgical treatment methods

Various methods of non surgical treatment will be discussed under following headings

- 1) Camouflage by changing inclination of anteriors
- 2) Extraction therapy
- 3) Distalization of mandibular arch
- 4) Mesialisation of maxillary dentition/ face mask
- 5) Reverse twin block
- 6) Multi loop edgewise archwire
- 7) Lingual appliances.
- 8) Invisalign

4.1 Camouflage by altering inclination of anteriors:

Non compensated class III malocclusion exhibiting retroclined upper anteriors and proclined lower anteriors can be better managed by altering their inclination to establish ideal overjet and overbite.²⁷ However, even compensated forms may be attempted by raising the inclination more than ideal.^{28,29} Several methods have been suggested for achieving this.

4.1.1 Prescription: Beggs /tip edge technique³⁰ favours incorporation of excess labial crown torque when compared to other pre-adjusted bracket prescriptions, because of increased range of tipping,³¹ favours correction of anterior crossbite.

Certain modifications in MBT prescriptions have been suggested to aid class III cases. Placement of contra-lateral canine brackets on the lower canines³² encourage the crowns to tip distally, this distal crown tipping in turn helps in distal

movement of lower anteriors to camouflage class III reducing anchorage strain.

4.1.2 Mechanics: Class III elastics^{33,34} favour proclination of upper anteriors along with mesialisation of the whole arch, Simultaneously retroclination of lower anteriors and distalisation of lower arch is favoured. However, unnecessary extrusion of teeth increases lower anterior facial height.

Catania³⁵ suggested tie forward technique to favour forward displacement of maxillary dentition along with point A to help cases of maxillary retrusion. Alternately beta titanium advancing loops may be used. Occlusal bite plate in lower arch / angulated bite plane³⁴ are helpful to correct crossbite in anterior region. Utility arch³⁶ may be used in upper arch for protrusion of anteriors, in combination with regular class III elastics.

4.1.3 Limitations of this approach: Proclining incisors beyond ideal may pose periodontal issues³⁷. Thongudomporn et al³⁴ in 2014 studied labial alveolar bone thickness change during proclination. When light forces were applied for proclining incisors, growing children maintained labial alveolar bone thickness because of high bone turn over in them. However, Greater caution must be taken in cases of adult class III.

Burns et al³⁸ identified limits for incisal movement to compensate for class III. Accordingly upper anteriors may be proclined upto 120° to sella nasion line and lower anteriors may be retroclined upto 80° to mandibular plane in most cases without deleterious effects to the periodontium (*Figure: 1*) However, proper diagnosis and realistic treatment objectives are necessary to prevent undesirable sequelae.

4.2 Extraction therapy:

Few cases of class III may be better managed with extraction therapy. Extraction of teeth in lower arch helps in

camouflaging class III, this may be in combination with upper teeth in instances showing arch length tooth material discrepancy in upper arch.

Usual extraction patterns suggested are discussed here under:

4.2.1 Extraction of lower single incisor³⁹:

Extraction of one mandibular incisor can lead to satisfactory treatment results in adults with mild Class III malocclusion and reduced overbite, particularly when coupled with a large mandibular intercanine width and minor crowding, and some mandibular tooth size excess. Overjet increase by 1-1.5mm may be observed⁴⁰

4.2.2 Extraction of lower premolars^{41,42}

:Extraction of mandibular bicusps, while maintaining full complement of maxillary teeth, compensates for the skeletal imbalance by retracting the lower incisors to achieve positive overjet. The challenge with this treatment lies in avoiding excessive retroclination on the of mandibular incisors, settling the posterior occlusion, and preventing supraeruption of the hanging maxillary second molars.⁴³ As many class iii patients show hyperdivergence with thin alveolar housing and reduced symphyseal thickness, extraction and retraction may cause dehiscence, fenestration across lingual cortical plate and stability of such retraction is questionable.

4.2.3 Extraction of second molars:

Cases of class III with open bite benefit with extraction of all second molars.⁴⁴ Sato et al⁴⁵ in 1988 studied posterior tooth-to-denture base discrepancy and suggested extraction of all second molars as an approach to treat class III. They suggested that the forward displacement of the mandible was associated with inferiorly positioned maxillary molars and/or superiorly positioned mandibular molars caused by the "squeezing out" effect of posterior discrepancy, which provides a less steep maxillary occlusal plane in the denture frame.

To aid in anchorage control during retraction of lower anteriors temporary

anchorage devices, modified nance lingual arch were frequently used.

4.3 Distalization of whole mandibular arch:

Distalization of whole mandibular arch⁴⁶⁻⁵⁰ is difficult to achieve in adults. Choice of technique should take into consideration lower anterior facial height of the patient. In hyperdivergent cases distalisation would worsen the profile. Extraction of third molars and distalisation using various methods like mandibular headgear, lip bumper, Franzulum appliance, lingual arch with distal extension, Jones jig, and class III elastics can be used.

With the help of mini implant anchorage distalisation has become more effective than before. Use of mini implants⁵¹⁻⁵⁹ and mini plates are valuable options for distalizing mandibular teeth. Simultaneous protraction of maxilla using class III elastics can also be undertaken. Suggested locations for implant placement are- retromolar area, interdental area between 6 & 7 or 5 & 6.

4.3.1 Retromolar area⁵⁹

has advantage of having a thick cortical bone, far from roots of teeth and as they do not interfere with distal movement there is no need for replacement during the course of distalization. Care should be taken during implant placement as any slippage can cause damage and also treatment lag of around six months to be given after extraction of third molars to ensure formation of good quality bone for implant stability. Clearance of bite is necessary in this region which may necessitate extraction of upper third molars also. Direct usage of miniscrews in the retromolar area took less time and more bodily movement to retract the lower arch without cooperation of the patients and was a better choice for the patients with potential temporomandibular joint disorders problems.⁵⁷

4.3.2 Implant between 6 and 7

is the most preferred location according to density of bone but placing in this region can be

difficult for operator and also thick mucobuccal fold can cause implant failure and inaccessible.

4.3.3 Implant between 5 and 6 is relatively easy for operator and comfortable for patient but needs replacement after few mm of distalization.

4.3.4 External oblique ridge was also suggested as an implant placement site for distalisation⁵⁹

4.4 Mesialization of maxillary dentition:

Although early treatment with facemask is most effective, reports suggest it can provide a viable option for older children as well. Recent report⁶⁰ suggested that facemask is effective in young adults. However consideration must be given to patient lower anterior facial height which may increase with face mask therapy if line of force is not directed towards center of maxilla. Implant assisted mesialisation of maxillary dentition with the help of appliances like mesial slider⁶¹ is an alternate approach for correcting class III molar relation.

4.5 Reverse twin block^{62, 63}:

In adult patients reporting with TMJ pain it was noticed that use of a reverse twin block helped in creating positive overjet while also relieving TMJ symptoms.

4.6 Multiloop edgewise archwire:

Cases showing mesially inclined mandibular posteriors would favour a multiloop edge wise system which distalizes the mandibular segment and also helps to change the occlusal plane to a favourable one.⁶⁴⁻⁶⁶ This is widely used to solve in particular class III open bite cases.

4.7 Lingual appliance:

Customised lingual appliances⁶⁷ can be effectively used in class III cases to achieve remarkable results. Planned inclinations of

upper and lower anteriors may be set in customised appliance.

4.8 Invisalign:

Simple cases of class III can also be managed with Invisalign therapy.⁶⁸

5. Vertical control in class III hyperdivergent cases:

Components of class III malocclusion suggests clear predominance of hyperdivergence. Hence it is important to control vertical dimension while achieving sagittal correction. Intrusion of posteriors and flattening of occlusal plane are valuable means for controlling vertical dimension in class III hyperdivergent subjects (Figure 2). Various means for achieving this are:

5.1 Mandibular cervical headgear:

Mandibular cervical headgear when used for distalizing the mandibular dentition also helps in intruding the posteriors thus enhances control in vertical dimension.⁶⁹

5.2 Highpull headgear with J hook in lower arch:

With the use of extraoral headgear⁷⁰ (high-pull J-hook) on the lower arch during the retraction of canines and incisors, efficient vertical control and maintenance of lower occlusal plane would be achieved, promoting a counter clockwise rotation, fundamental for the correction of the anterior open bite (Figure 3)

5.3 MEAW:

Multiloop edge wise arch wire with progressive increase in tip back bends towards posteriors combined with anterior elastics helps in controlling vertical dimension (Figure 4)

5.4 Archwires and elastics:

Use of accentuated curve of spee in upper arch and reverse curve of spee in lower arch in combination with anterior vertical elastics- Modified Kims technique proposed by Enacar⁷¹ helps in controlling vertical dimension.

Use of class III elastics from mini implant placed in upper posterior region to lower anteriors functions similar to high pull headgear attached to J hook and favours vertical control.⁷²

5.5 Skeletal anchorage:

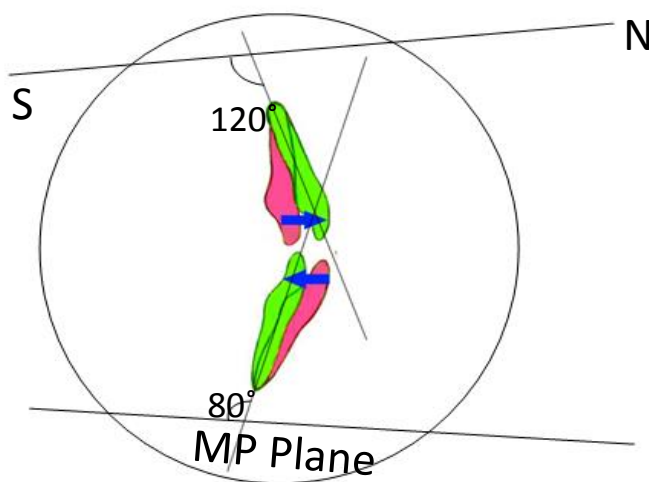


Figure 1: Limits for incisal movement to compensate for class III according to Burns et al

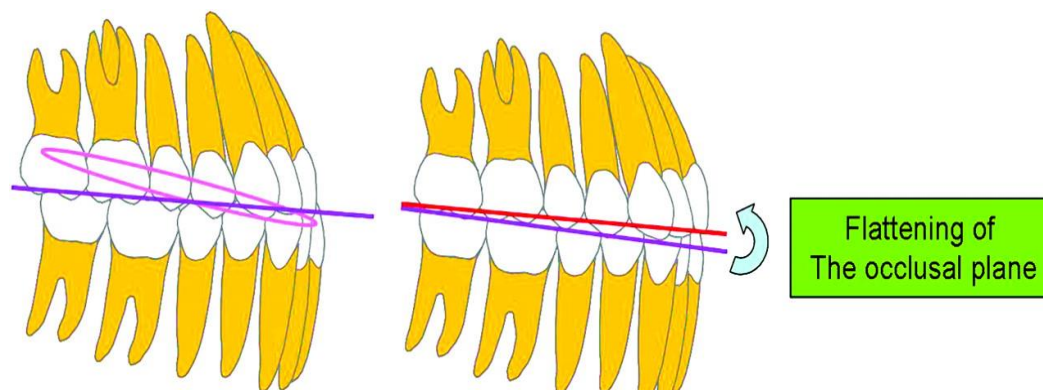


Figure 2: Vertical control in class III hyperdivergent cases⁶⁶

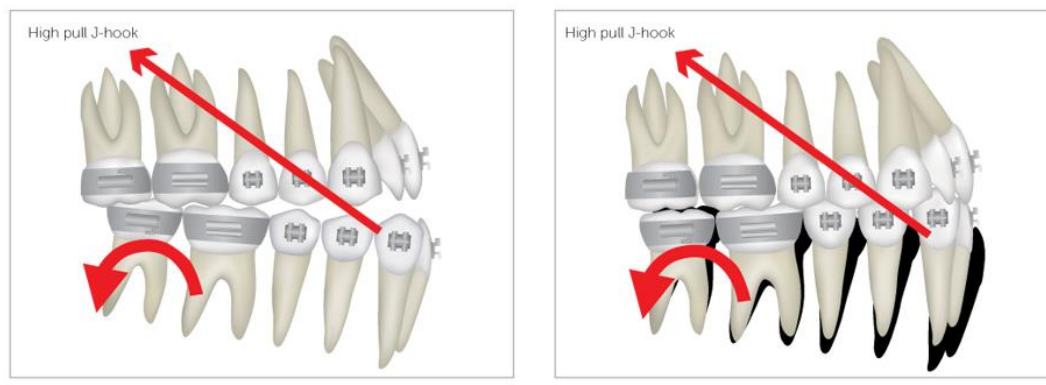


Figure 3: High pull headgear with j hook⁷²

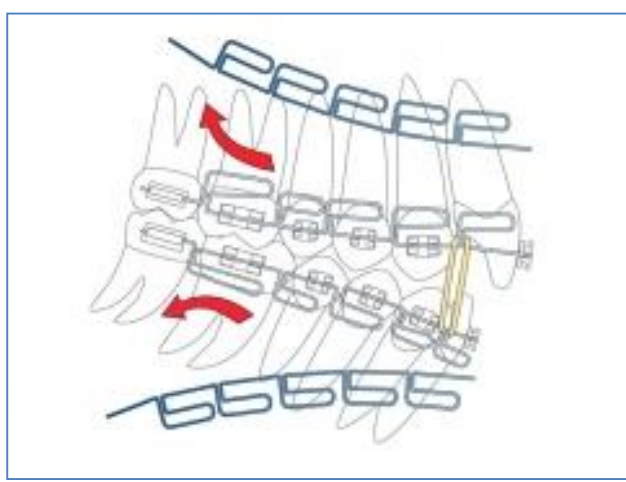


Figure 4: MEAW appliance for controlling vertical dimension

References

- I. Massler M, Frankel JM. Prevalence of malocclusion in children aged 14 to 18 years. American journal of orthodontics. 1951 Oct 31;37(10):751-68.
- II. Haynes S. The prevalence of malocclusion in English children aged 11-12 years. In Report of the Congress. European Orthodontic Society 1970 (p. 89).
- III. Thilander B, Myrberg N. The prevalence of malocclusion in Swedish schoolchildren. European Journal of Oral Sciences. 1973 Feb 1;81(1):12-20.
- IV. Altemus LA. Frequency of the incidence of malocclusion in American Negro children aged twelve to sixteen. The Angle Orthodontist. 1959 Oct;29(4):189-200.
- V. Hardy DK, Cubas YP, Orellana MF. Prevalence of angle class III

- malocclusion: a systematic review and meta-analysis.
- VI. Ellis E, McNamara JA. Components of adult Class III malocclusion. *Journal of oral and maxillofacial surgery*. 1984 May 31;42(5):295-305.
- VII. Tseng YC, Pan CY, Chou ST, Liao CY, Lai ST, Chen CM, Chang HP, Yang YH. Treatment of adult Class III malocclusions with orthodontic therapy or orthognathic surgery: receiver operating characteristic analysis. *American Journal of Orthodontics and Dentofacial Orthopedics*. 2011 May 31;139(5):e485-93.
- VIII. Moyers RE. *Handbook of orthodontics*. Year Book Medical Pub; 1988.
- IX. Negi KS, Sharma KR. Treatment of pseudo Class III malocclusion by modified Hawleys appliance with inverted labial bow. *Journal of Indian Society of Pedodontics and Preventive Dentistry*. 2011 Jan 1;29(1):57.
- X. Sharma PS, Brown RV. Pseudo mesiocclusion: diagnosis and treatment. *ASDC journal of dentistry for children*. 1968 Sep;35(5):385-92.
- XI. Graber TM: *Orthodontics: Principles and practice*. 2nd ed. Philadelphia: WB Saunders Company; 1967. p. 243-8
- XII. Rabie AB, Gu Y. Orthodontics: Management of pseudo Class III malocclusion in southern Chinese children. *British dental journal*. 1999 Feb 27;186(4):183-7.
- XIII. Reyes A, Serret L, Peguero M, Tanaka O. Diagnosis and Treatment of Pseudo-Class III Malocclusion. *Case reports in dentistry*. 2014 Nov 24;2014.
- XIV. Gravely JF. A study of the mandibular closure path in Angle Class III relationship. *British journal of orthodontics*. 1984 Apr;11(2):85-91.
- XV. Rabie AB, Gu Y. Diagnostic criteria for pseudo-Class III malocclusion. *American Journal of Orthodontics and Dentofacial Orthopedics*. 2000 Jan 31;117(1):1-9
- XVI. Krishnaswamy NR, Varghese BT, Faizee SH, Jayakumar G, Anand MK. Three-dimensional treatment planning and management of an asymmetrical skeletal Class III malocclusion and open bite. *Journal of clinical orthodontics: JCO*. 2014 Jan;48(1):47.
- XVII. Hidaka O, Adachi S, Takada K. The difference in condylar position between centric relation and centric occlusion in pretreatment Japanese orthodontic patients. *The Angle orthodontist*. 2002 Aug;72(4):295-301.
- XVIII. Guyer EC, Ellis III EE, McNamara Jr JA, Behrents RG. Components of Class III malocclusion in juveniles and adolescents. *The Angle orthodontist*. 1986 Jan;56(1):7-30.
- XIX. Spalj S, Mestrovic S, LAPTER VARGA M, Slaj M. Skeletal components of class III malocclusions and compensation mechanisms. *Journal of oral rehabilitation*. 2008 Aug 1;35(8):629-37.
- XX. Adamidis IP, Spyropoulos MN. Hyoid bone position and orientation in Class I and Class III malocclusions. *American Journal of Orthodontics and Dentofacial*

- Orthopedics. 1992 Apr 30;101(4):308-12.
- XXI. GUAY AH, MAXWELL DL, BEECHER R. A radiographic study of tongue posture at rest and during the phonation of/s/in class III malocclusion. The Angle orthodontist. 1978 Jan;48(1):10-22.
- XXII. Meenakshi S, Jagannathan N. Assessment of Lingual Frenulum Lengths in Skeletal Malocclusion. Journal of clinical and diagnostic research: JCDR. 2014 Mar;8(3):202.
- XXIII. Chanson P, Salenave S. Acromegaly. Orphanet journal of rare diseases. 2008 Jun 25;3(1):17.
- XXIV. Kook YA, Kim SH. Treatment of Class III relapse due to late mandibular growth using miniscrew anchorage. Journal of clinical orthodontics: JCO. 2008 Jul;42(7):400-11.
- XXV. Sakai A, Haraguchi S, Takada K. Orthodontic camouflage of a late adolescent patient with Class III malocclusion. orthodontic waves. 2006 Oct 31;65(3):127-33.
- XXVI. Lin J, Gu Y. Preliminary investigation of nonsurgical treatment of severe skeletal Class III malocclusion in the permanent dentition. The Angle Orthodontist. 2003 Aug;73(4):401-10.
- XXVII. Proffit WR, Fields HW, Sarver DM.
- XXVIII. Cozzani G, Cozzani P, Mazzotta L, Cozzani M. Non-surgical, non-extractive treatment of a severe class III malocclusion in permanent dentition: Follow-up of a case 24years posttreatment. International Orthodontics. 2013 Dec 31;11(4):457-73.
- XXIX. Estelita S, Janson G, Chiqueto K. Extreme Dental Compensation in an Adult Skeletal Class III Malocclusion: 3-Year Follow-up of a Successfully Compromised Treatment. International journal of orthodontics (Milwaukee, Wis.). 2014 Dec;26(2):69-76.
- XXX. Kesling CK. The Tip-Edge concept: eliminating unnecessary anchorage strain. J Clin Orthod. 1992 Mar;26(3):165-78.
- XXXI. Miyajima K, Iizuka T. Treatment mechanics in Class III open bite malocclusion with Tip Edge technique. American journal of orthodontics and dentofacial orthopedics. 1996 Jul 31;110(1):1-7.
- XXXII. Thickett E, Taylor NG, Hodge T. Choosing a pre-adjusted orthodontic appliance prescription for anterior teeth. Journal of orthodontics. 2007 Jun;34(2):95-100.
- XXXIII. Thongudomporn U, Charoemratrote C, Jearapongpakorn S. Changes of anterior maxillary alveolar bone thickness following incisor proclination and extrusion. Angle Orthodontist. 2014 Sep 10.
- XXXIV. Xu L, Chen L, Lu B, Zhang Y, Gao Z, Liu H. [Orthodontic treatment of adult skeletal crossbite with mandibular deviation]. Zhonghua kou qiang yi xue za zhi= Zhonghua kouqiang yixue zazhi= Chinese journal of stomatology. 2014 May;49(5):299-303.
- XXXV. Catania JA, Cohen BD, Deeney MR. The use of labial root torque and the tie-forward technique in the treatment of maxillary skeletal retrusion and severe arch length discrepancy. American Journal of

- Orthodontics and Dentofacial Orthopedics. 1990 Jul 31;98(1):12-8.
- XXXVI. Gelgor IE, Karaman AI. Non-surgical treatment of Class III malocclusion in adults: two case reports. Journal of orthodontics. 2005 Jun;32(2):89-97.
- XXXVII. McLaughlin RP, Bennett JC, Trevisi HJ. Systemized orthodontic treatment mechanics. Elsevier Health Sciences; 2001.
- XXXVIII. Burns NR, Musich DR, Martin C, Razmus T, Gunel E, Ngan P. Class III camouflage treatment: what are the limits?. American Journal of Orthodontics and Dentofacial Orthopedics. 2010 Jan 31;137(1):9-e1.
- XXXIX. Hegde C, Hegde M. Mandibular incisor extractions in orthodontics: pitfalls and triumphs: a report of three cases. International journal of orthodontics (Milwaukee, Wis.). 2013 Dec;25(2):17-20.
- XL. Færøvig E, Zachrisson BU. Effects of mandibular incisor extraction on anterior occlusion in adults with Class III malocclusion and reduced overbite. American journal of orthodontics and dentofacial orthopedics. 1999 Feb 28;115(2):113-24.
- XLI. Kapadia RM, Shah AP, Diyora SD, Rathva VJ. Non-surgical treatment of skeletal class III malocclusion. BMJ case reports. 2014 Apr 10;2014:bcr2013202326.
- XLII. Valladares Neto J. Compensatory orthodontic treatment of skeletal Class III malocclusion with anterior crossbite. Dental press journal of orthodontics. 2014 Feb;19(1):113-22.
- XLIII. Zimmer B, Schenk-Kazan S. Dental compensation for skeletal Class III malocclusion by isolated extraction of mandibular teeth. Journal of Orofacial Orthopedics/Fortschritte der Kieferorthopädie. 2015 May 2;76(3):251-64.
- XLIV. Rey Mora D, Oberti G, Ealo M, Baccetti T. Camouflage of moderate Class III malocclusions with extraction of lower second molars and mandibular cervical headgear.
- XLV. Sato S, Suzuki Y. Relationship between the development of skeletal mesio-occlusion and posterior tooth-to-denture base discrepancy--its significance in the orthodontic reconstruction of skeletal Class III malocclusion. Nihon Kyosei Shika Gakkai zasshi= The journal of Japan Orthodontic Society. 1988 Dec;47(4):796-810.
- XLVI. Hisano M, Choo-ryung JC, Soma K. Nonsurgical correction of skeletal Class III malocclusion with lateral shift in an adult. American Journal of Orthodontics and Dentofacial Orthopedics. 2007 Jun 30;131(6):797-804.
- XLVII. Sakai Y, Kuroda S, Murshid SA, Takano-Yamamoto T. Skeletal Class III severe openbite treatment using implant anchorage. The Angle Orthodontist. 2008 Jan;78(1):157-66.
- XLVIII. Lima CE, Lima MT. Directional force treatment for an adult with Class III malocclusion and open bite. American journal of orthodontics and dentofacial orthopedics. 2006 Jun 30;129(6):817-24.
- XLIX. Chung KR, Kim SH, Choo H, Kook YA, Cope JB. Distalization of the mandibular dentition with mini-implants to correct a Class III

- malocclusion with a midline deviation. *American Journal of Orthodontics and Dentofacial Orthopedics*. 2010 Jan 31;137(1):135-46.
- L. Mou L, Xu G, Han Y, Ge Z. Distal movement of the mandibular dentition in the treatment of patients with Class III skeletal pattern. *Zhonghua kou qiang yi xue za zhi= Zhonghua kouqiang yixue zazhi= Chinese journal of stomatology*. 2015 Jun;50(6):373.
- LI. Chung K, Kim SH, Kook Y. C-orthodontic microimplant for distalization of mandibular dentition in Class III correction. *The Angle Orthodontist*. 2005 Jan;75(1):119-28.
- LII. Chung KR, Kim SH, Choo H, Kook YA, Cope JB. Distalization of the mandibular dentition with mini-implants to correct a Class III malocclusion with a midline deviation. *American Journal of Orthodontics and Dentofacial Orthopedics*. 2010 Jan 31;137(1):135-46.
- LIII. Agarwal S, Shah N, Yadav S, Nanda R. Mandibular arch retraction with retromolar skeletal anchorage in a Class III open-bite patient. *Journal of clinical orthodontics: JCO*. 2014 Dec;48(12):775-82.
- LIV. Creekmore TD, Eklund MK. The possibility of skeletal anchorage. *Journal of clinical orthodontics: JCO*. 1983 Apr;17(4):266.
- LV. Ye C, Zhihe Z, Zhao Q, Ye J. Treatment effects of distal movement of lower arch with miniscrews in the retromolar area compared with miniscrews in the posterior area of the maxillary. *Journal of Craniofacial Surgery*. 2013 Nov 1;24(6):1974-9.
- LVI. Farret MM, Benitez Farret MM. Skeletal class III malocclusion treated using a non-surgical approach supplemented with mini-implants: a case report. *Journal of orthodontics*. 2013 Sep;40(3):256-63.
- LVII. Anhoury PS. Retromolar miniscrew implants for Class III camouflage treatment. *Journal of clinical orthodontics: JCO*. 2013 Dec;47(12):706.
- LVIII. Kanomi R. Mini-implant for orthodontic anchorage. *Journal of clinical orthodontics: JCO*. 1997 Nov;31(11):763.
- LIX. Jing Y, Han X, Guo Y, Li J, Bai D. Nonsurgical correction of a Class III malocclusion in an adult by miniscrew-assisted mandibular dentition distalization. *American Journal of Orthodontics and Dentofacial Orthopedics*. 2013 Jun 30;143(6):877-87.
- LX. Jackson GW, Kravitz ND. Expansion/Facemask Treatment of an Adult Class III Malocclusion. *Case reports in dentistry*. 2014 Feb 19;2014.
- LXI. Wilmes B, Katyal V, Willmann J, Stocker B, Drescher D. Mini-implant-anchored Mesialslider for simultaneous mesialisation and intrusion of upper molars in an anterior open bite case: a three-year follow-up. *Australian orthodontic journal*. 2015 May;31(1):87-97.
- LXII. Shastri D, Nagar A, Tandon P. Treatment of pseudo-class III malocclusion with a modified reverse twin block and fixed appliances. *Journal of clinical*

- orthodontics: JCO. 2015 Jul;49(7):470-6.
- LXIII. Liu H, Li JX. Non-surgical treatment of an Angle Class III malocclusion in adults. *International journal of clinical and experimental medicine*. 2013;6(9):738.
- LXIV. Aguiar JH. Conservative treatment of Angle Class III malocclusion with anterior crossbite. *Dental press journal of orthodontics*. 2015 Aug;20(4):91-8.
- LXV. He S, Gao J, Wamalwa P, Wang Y, Zou S, Chen S. Camouflage treatment of skeletal Class III malocclusion with multiloop edgewise arch wire and modified Class III elastics by maxillary mini-implant anchorage. *The Angle Orthodontist*. 2013 Jan 11;83(4):630-40.
- LXVI. Baek SH, Shin SJ, Ahn SJ, Chang YI. Initial effect of multiloop edgewise archwire on the mandibular dentition in Class III malocclusion subjects. A three-dimensional finite element study. *The European Journal of Orthodontics*. 2008 Feb 1;30(1):10-5.
- LXVII. Galletti C, Fauquet-Roure C, Raybaud P. Treatment of class III malocclusions in adults using the Incognito® lingual technique. *International Orthodontics*. 2010 Sep 30;8(3):227-52.
- LXVIII. Needham R, Waring DT, Malik OH. Invisalign treatment of Class III malocclusion with lower-incisor extraction. *Journal of clinical orthodontics: JCO*. 2015 Jul;49(7):429-41.
- LXIX. Oberti G, Ortho C, Angel D, Ortho C. Mandibular cervical headgear in orthopedic and orthodontic treatment of class III cases. *World J Orthod*. 2006;7:165-176.
- LXX. Kuroda Y, Kuroda S, Alexander RG, Tanaka E. Adult Class III Treatment Using a J-Hook Headgear to the Mandibular Arch. *The Angle Orthodontist*. 2010 Mar;80(2):336-43.
- LXXI. Enacar A, Ugur T, Toroglu S. A method for correction of open bite. *Journal of clinical orthodontics: JCO*. 1996 Jan;30(1):43-8.
- LXXII. Sobral MC, Habib FA, Nascimento AC. Vertical control in the Class III compensatory treatment. *Dental press journal of orthodontics*. 2013 Apr;18(2):141-59.